

12.6E: Dermatomes

A dermatome is an area of skin that is supplied by a single spinal nerve, and a myotome is a group of muscles that a single spinal nerve root innervates.

Learning Objectives

- Describe dermatomes and how they relate to the peripheral nervous system

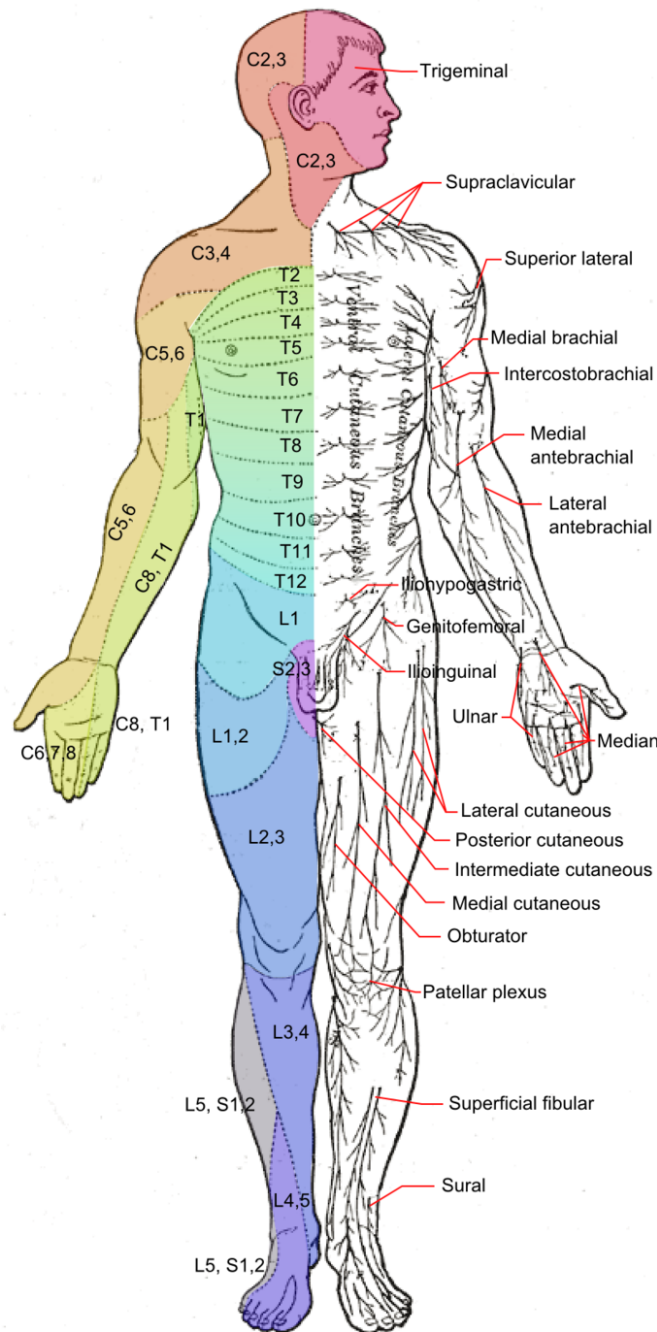
Key Points

- There are eight cervical nerves, twelve thoracic nerves, five lumbar nerves and five sacral nerves. Each of these nerves relays sensation, including pain, from a particular region of skin to the brain.
- Along the thorax and abdomen, the dermatomes are like a stack of discs, with each section supplied by a different spinal nerve. The pattern is different along the arms and the legs. The dermatomes run longitudinally along the limbs, so that each half of the limb has a different dermatome.
- Dermatomes have clinical significance, especially in the diagnosis of certain diseases. Symptoms that follow a dermatome, such as pain or a rash, may indicate a pathology that involves the related nerve root. Examples include dysfunction of the spine or a viral infection.

Key Terms

- **shingles:** Also known as herpes zoster, shingles is an acute viral inflammation of the sensory ganglia of spinal and cranial nerves associated with a vesicular eruption and neuralgic pains and caused by reactivation of the poxvirus causing chicken pox.
- **chickenpox:** A common childhood disease caused by the varicella-zoster virus.

A dermatome is an area of skin that is supplied by a single spinal nerve. There are eight cervical nerves, twelve thoracic nerves, five lumbar nerves and five sacral nerves. Each of these nerves relays sensation, including pain, from a particular region of the skin to the brain.



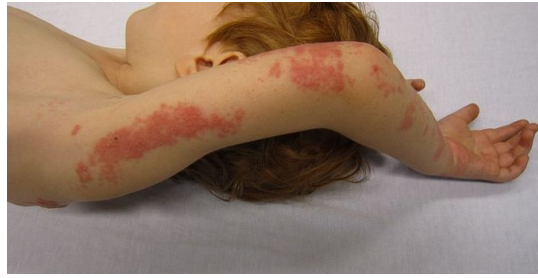Dermatomes: Dermatomes are areas of skin supplied by sensory neurons that arise from a spinal nerve ganglion. Dermatomes and the associated major cutaneous nerves are shown here in a ventral view.

Along the thorax and abdomen, the dermatomes are like a stack of discs, with each section supplied by a different spinal nerve. Along the arms and the legs, the pattern is different. The dermatomes run longitudinally along the limbs, so that each half of the limb has a different dermatome.

Although the general pattern is similar in all people, the precise areas of innervation are as unique to an individual as fingerprints.

Dermatomes have clinical significance, especially in the diagnosis of certain diseases. Symptoms that follow a dermatome, such as pain or a rash, may indicate a pathology that involves the related nerve root. Examples include dysfunction of the spine or a viral infection.

Viruses that remain dormant in nerve ganglia, such as the varicella zoster virus that causes both chickenpox and shingles, often cause either pain, rash, or both in a pattern defined by a dermatome.



Shingles rash: The shingles rash appears across a dermatome. In this patient, one of the dermatomes in the arm is affected, restricting the rash to the length of the back of the arm.

Shingles is one of the only diseases that causes a rash in a dermatomal pattern, and as such, this is its defining symptom. The rash of shingles is almost always restricted to a specific dermatome, such as on the chest, leg, or arm caused by the residual varicella zoster virus infection of the nerve that supplies that area of skin. Shingles typically appears years or decades after recovery from chickenpox.

Myotome

A myotome is the group of muscles that a single spinal nerve root innervates. The myotome is the motor equivalent of a dermatome.

The myotome distributions of the upper and lower extremities are listed below:

- C1/C2: Neck flexion / extension
- C3: Neck lateral flexion
- C4: Shoulder elevation
- C5: Shoulder abduction
- C6: Elbow flexion/wrist extension
- C7: Elbow extension/wrist flexion
- C8: Finger flexion
- T1: Finger abduction
- L2: Hip flexion
- L3: Knee extension
- L4: Ankle dorsi-flexion
- L5: Great toe extension
- S1: Ankle plantar flexion/ankle eversion/hip extension
- S2: Knee flexion
- S3–S4: Anal reflex

The testing of myotomes provides the clinician with information about the level in the spine where a lesion may be present. During testing, the clinician looks for muscle weakness of a particular group of muscles. Results may indicate lesions to the spinal cord nerve root, or intervertebral disc herniation that presses on the spinal nerve roots.

12.6E: Dermatomes is shared under a [CC BY-SA](https://creativecommons.org/licenses/by-sa/4.0/) license and was authored, remixed, and/or curated by LibreTexts.