

12.6F: Function and Physiology of the Spinal Nerves

Spinal nerves connect the brain and spinal cord to the limbs and organs of the body.

Learning Objectives

- Describe the function and physiology of the spinal nerves

Key Points

- Spinal nerves, considered part of the peripheral nervous system, generally refer to mixed spinal nerves, which carry motor, sensory, and autonomic information between the brain and spinal cord and the rest of the body.
- The cervical spinal nerves innervate the muscles and provide sensation for the head, neck, and diaphragm, as well as the upper limbs and back.
- The lumbar, sacral, and coccygeal nerves combine to form the lumbosacral plexus.
- The spinal cord can be divided into the lateral, posterior, and medial cord, each segment of which gives rise to specific nerves and serves specific areas of the body.
- The somatic nervous system is responsible for voluntary body movements, receiving information from afferent fibers and contracting muscles with efferent fibers.
- The autonomic nervous system involves the visceral organs and regulates involuntary movements or unconscious actions.
- The sympathetic nervous system is responsible for the fight or flight reaction under stressful conditions, while the parasympathetic nervous system conserves energy after high stress situations or during rest and digesting.
- The primary neurotransmitters of the peripheral nervous system (PNS) are acetylcholine and noradrenaline, though other neurotransmitters are also present. Acetylcholine acts on two sets of receptors, muscarinic and nicotinic cholinergic receptors.

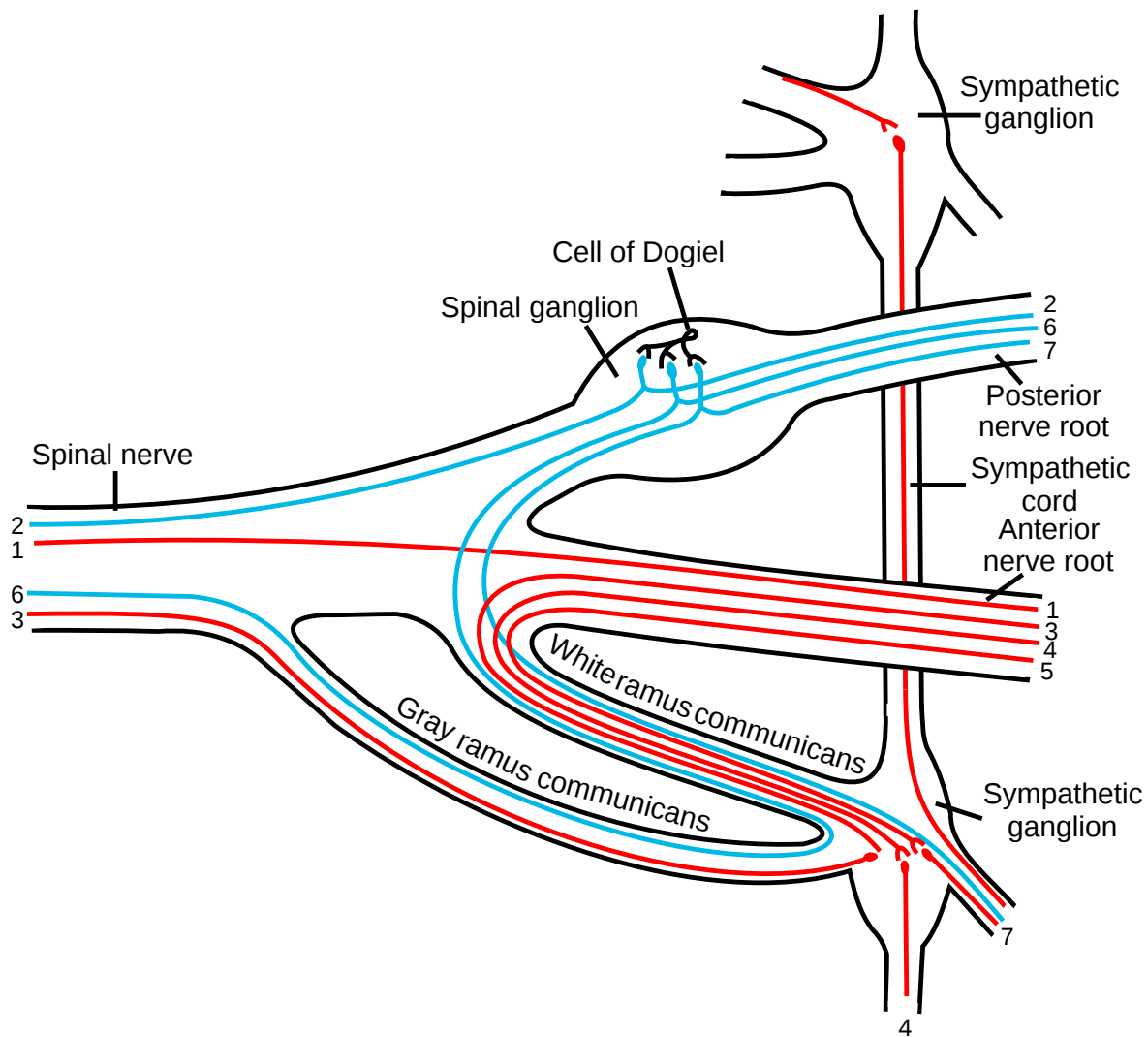
Key Terms

- **nicotinic:** Excitatory acetylcholine receptors.
- **mixed spinal nerve:** A nerve that carries motor, sensory, and autonomic signals between the spinal cord and the body.
- **peripheral nervous system:** The nerves and ganglia outside of the brain and spinal cord.
- **muscarinic:** Acetylcholine receptors that can be both excitatory and inhibitory.

Review of Peripheral Nervous System Structure

The peripheral nervous system (PNS) consists of the nerves and ganglia outside of the brain and spinal cord. The main function of the PNS is to connect the central nervous system (CNS) to the limbs and organs.

Unlike the CNS, the PNS is not protected by the bones of the spine and skull, or by the blood–brain barrier, leaving it exposed to toxins and mechanical injuries. The peripheral nervous system is divided into the somatic nervous system and the autonomic nervous system.



Spinal nerve: This diagram indicates the formation of a typical spinal nerve from the dorsal and ventral roots. Numbers indicate the types of nerve fibers: 1 somatic efferent, 2 somatic afferent, 3–5 sympathetic efferent, 6–7 sympathetic afferent.

The peripheral nervous system includes 12 cranial nerves and 31 pairs of spinal nerves that provide communication from the CNS to the rest of the body by nerve impulses to regulate the functions of the human body. The term spinal nerve generally refers to a mixed spinal nerve, which carries motor, sensory, and autonomic signals between the spinal cord and the body.

Spinal Nerve Correspondences

Each pair of spinal nerves roughly correspond to a segment of the vertebral column: 8 cervical spinal nerve pairs (C1–C8), 12 thoracic pairs (T1–T12), 5 lumbar pairs (L1–L5), 5 sacral pairs (S1–S5), and 1 coccygeal pair.

- The first 4 cervical spinal nerves, C1 through C4, split and recombine to produce a variety of nerves that subserve the neck and back of the head.
- The spinal nerve C1 (suboccipital nerve) provides motor innervation to muscles at the base of the skull.
- C2 and C3 form many of the nerves of the neck, and provides both sensory and motor control. These include the greater occipital nerve that provides sensation to the back of the head, the lesser occipital nerve that provides sensation to the area behind the ears, the greater auricular nerve, and the lesser auricular nerve.
- The phrenic nerve arises from nerve roots C3, C4, and C5. It innervates the diaphragm to enable breathing. If the spinal cord is transected above C3, then spontaneous breathing is not possible.
- The last four cervical spinal nerves, C5 through C8, and the first thoracic spinal nerve, T1, combine to form the brachial plexus, or plexus brachialis, a tangled array of nerves, splitting, combining and recombining to form the nerves that subserve the upper

limb region and upper back. Although the brachial plexus may appear tangled, it is highly organized and predictable with little variation among people.

Lumbosacral Plexus

The anterior divisions of the lumbar, sacral, and coccygeal nerves form the lumbosacral plexus, the first lumbar nerve being frequently joined by a branch from the twelfth thoracic. For descriptive purposes, this plexus is usually divided into three parts: lumbar plexus, sacral plexus, and pudendal plexus.

Autonomic Nervous System Function (ANS)

The sympathetic division typically functions in actions that need quick responses. The parasympathetic division functions with actions that do not require immediate reaction.

The sympathetic system is often considered the fight or flight system, while the parasympathetic system is often considered the rest and digest or feed and breed system.

Some typical actions of the sympathetic and parasympathetic systems are listed below.

Sympathetic Nervous System

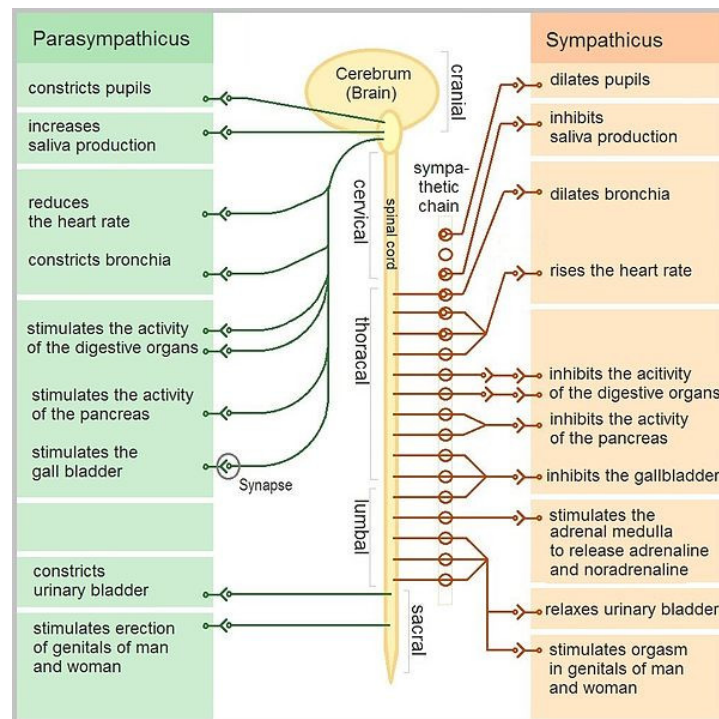
- Diverts blood flow away from the gastrointestinal (GI) tract and skin via vasoconstriction.
- Enhances blood flow to skeletal muscles and the lungs.
- Dilates bronchioles of the lung by circulating epinephrine to allow for greater alveolar oxygen exchange.
- Increases the heart rate and contractility of cardiac muscle for enhanced blood flow to skeletal muscles.
- Dilates pupils and relaxes the ciliary muscle to the lens for far vision.
- Provides vasodilation for the coronary vessels of the heart.
- Constricts all the intestinal sphincters and the urinary sphincter.
- Inhibits peristalsis.
- Stimulates orgasm.

Parasympathetic Nervous System

- Dilates blood vessels that lead to the GI tract to increase blood flow; this is important following food consumption due to the greater metabolic demands placed on the body by the gut.
- Constricts the bronchiolar diameter when the need for oxygen has diminished.
- Manages heart control via dedicated cardiac branches of the vagus and thoracic spinal accessory nerves.
- Constricts the pupil and contracts the ciliary muscles to facilitate accommodation for closer vision.
- Stimulates salivary gland secretion and accelerates peristalsis to mediate the digestion of food.
- PNS nerves are involved in the erection of genital tissues via the pelvic splanchnic nerves 2–4. They are also responsible for stimulating sexual arousal.

Neurotransmitters

- Acetylcholine is the preganglionic neurotransmitter for both divisions of the ANS, as well as the postganglionic neurotransmitter of parasympathetic neurons.
- Nerves that release acetylcholine are said to be cholinergic. In the parasympathetic system, ganglionic neurons use acetylcholine as a neurotransmitter to stimulate muscarinic receptors.
- At the adrenal medulla, there is no postsynaptic neuron. Instead the presynaptic neuron releases acetylcholine to act on nicotinic receptors.
- Stimulation of the adrenal medulla releases adrenaline (epinephrine) into the bloodstream, which acts on adrenoceptors, producing a widespread increase in sympathetic activity.



Autonomic nervous system: The functions of the parasympathetic and sympathetic nervous systems are detailed.

Somatic Nervous System Function (SoNS)

The somatic nervous system consists of afferent and efferent nerves and is associated with the voluntary control of skeletal muscle movements. The afferent nerves are responsible for relaying sensations from the body to the central nervous system (CNS), while the efferent nerves are responsible for sending out commands from the CNS to the body to stimulate muscle contraction.

Upper motor neurons release acetylcholine. Acetylcholine is released from the axon terminal knobs of alpha motor neurons and received by postsynaptic receptors (nicotinic acetylcholine receptors) of muscles, thereby relaying the stimulus to contract muscle fibers.

LICENSES AND ATTRIBUTIONS

CC LICENSED CONTENT, SHARED PREVIOUSLY

- Curation and Revision. **Authored by:** Boundless.com. **Provided by:** Boundless.com. **License:** [CC BY-SA: Attribution-ShareAlike](#)

CC LICENSED CONTENT, SPECIFIC ATTRIBUTION

- Spinal nerves. **Provided by:** Wikipedia. **Located at:** [en.Wikipedia.org/wiki/Spinal_nerves](https://en.wikipedia.org/wiki/Spinal_nerves). **License:** [CC BY-SA: Attribution-ShareAlike](#)
- Spinal nerves. **Provided by:** Wikipedia. **Located at:** [en.Wikipedia.org/wiki/Spinal_nerves](https://en.wikipedia.org/wiki/Spinal_nerves). **License:** [CC BY-SA: Attribution-ShareAlike](#)
- dorsal root. **Provided by:** Wikipedia. **Located at:** [en.Wikipedia.org/wiki/dorsal%20root](https://en.wikipedia.org/wiki/dorsal%20root). **License:** [CC BY-SA: Attribution-ShareAlike](#)
- autonomic. **Provided by:** Wiktionary. **Located at:** en.wiktionary.org/wiki/autonomic. **License:** [CC BY-SA: Attribution-ShareAlike](#)
- intervertebral foramen. **Provided by:** Wikipedia. **Located at:** [en.Wikipedia.org/wiki/intervertebral%20foramen](https://en.wikipedia.org/wiki/intervertebral%20foramen). **License:** [CC BY-SA: Attribution-ShareAlike](#)
- Spinal nerves. **Provided by:** Wikipedia. **Located at:** [en.Wikipedia.org/wiki/Spinal_nerves%23Anatomy](https://en.wikipedia.org/wiki/Spinal_nerves%23Anatomy). **License:** [CC BY-SA: Attribution-ShareAlike](#)
- Spinal Nerve. **Provided by:** Wikipedia. **Located at:** [en.Wikipedia.org/wiki/Spinal_nerve](https://en.wikipedia.org/wiki/Spinal_nerve). **License:** [CC BY-SA: Attribution-ShareAlike](#)

- Foraminaintervertebralia. **Provided by:** Wikipedia. **Located at:** [en.Wikipedia.org/wiki/File:Fo...ertebralia.png](https://en.wikipedia.org/wiki/File:Fo...ertebralia.png). License: [CC BY-SA: Attribution-ShareAlike](#)
- Spinal nerves. **Provided by:** Wikipedia. **Located at:** [en.Wikipedia.org/wiki/Spinal_nerves%23Anatomy](https://en.wikipedia.org/wiki/Spinal_nerves%23Anatomy). License: [CC BY-SA: Attribution-ShareAlike](#)
- dorsal ramus. **Provided by:** Wikipedia. **Located at:** [en.Wikipedia.org/wiki/dorsal%20ramus](https://en.wikipedia.org/wiki/dorsal%20ramus). License: [CC BY-SA: Attribution-ShareAlike](#)
- meningeal branches. **Provided by:** Wikipedia. **Located at:** [en.Wikipedia.org/wiki/meningeal%20branches](https://en.wikipedia.org/wiki/meningeal%20branches). License: [CC BY-SA: Attribution-ShareAlike](#)
- Spinal nerves. **Provided by:** Wikipedia. **Located at:** [en.Wikipedia.org/wiki/Spinal_nerves%23Anatomy](https://en.wikipedia.org/wiki/Spinal_nerves%23Anatomy). License: [CC BY-SA: Attribution-ShareAlike](#)
- Spinal Nerve. **Provided by:** Wikipedia. **Located at:** [en.Wikipedia.org/wiki/Spinal_nerve](https://en.wikipedia.org/wiki/Spinal_nerve). License: [CC BY-SA: Attribution-ShareAlike](#)
- Foraminaintervertebralia. **Provided by:** Wikipedia. **Located at:** [en.Wikipedia.org/wiki/File:Fo...ertebralia.png](https://en.wikipedia.org/wiki/File:Fo...ertebralia.png). License: [CC BY-SA: Attribution-ShareAlike](#)
- Gray819. **Provided by:** Wikipedia. **Located at:** [en.Wikipedia.org/wiki/File:Gray819.png](https://en.wikipedia.org/wiki/File:Gray819.png). License: [Public Domain: No Known Copyright](#)
- Nerve plexus. **Provided by:** Wikipedia. **Located at:** [en.Wikipedia.org/wiki/Nerve_plexus](https://en.wikipedia.org/wiki/Nerve_plexus). License: [CC BY-SA: Attribution-ShareAlike](#)
- coccygeal plexus. **Provided by:** Wikipedia. **Located at:** [en.Wikipedia.org/wiki/coccygeal%20plexus](https://en.wikipedia.org/wiki/coccygeal%20plexus). License: [CC BY-SA: Attribution-ShareAlike](#)
- brachial plexus. **Provided by:** Wikipedia. **Located at:** [en.Wikipedia.org/wiki/brachial%20plexus](https://en.wikipedia.org/wiki/brachial%20plexus). License: [CC BY-SA: Attribution-ShareAlike](#)
- nerve plexus. **Provided by:** Wikipedia. **Located at:** [en.Wikipedia.org/wiki/nerve%20plexus](https://en.wikipedia.org/wiki/nerve%20plexus). License: [CC BY-SA: Attribution-ShareAlike](#)
- Spinal nerves. **Provided by:** Wikipedia. **Located at:** [en.Wikipedia.org/wiki/Spinal_nerves%23Anatomy](https://en.wikipedia.org/wiki/Spinal_nerves%23Anatomy). License: [CC BY-SA: Attribution-ShareAlike](#)
- Spinal Nerve. **Provided by:** Wikipedia. **Located at:** [en.Wikipedia.org/wiki/Spinal_nerve](https://en.wikipedia.org/wiki/Spinal_nerve). License: [CC BY-SA: Attribution-ShareAlike](#)
- Foraminaintervertebralia. **Provided by:** Wikipedia. **Located at:** [en.Wikipedia.org/wiki/File:Fo...ertebralia.png](https://en.wikipedia.org/wiki/File:Fo...ertebralia.png). License: [CC BY-SA: Attribution-ShareAlike](#)
- Gray819. **Provided by:** Wikipedia. **Located at:** [en.Wikipedia.org/wiki/File:Gray819.png](https://en.wikipedia.org/wiki/File:Gray819.png). License: [Public Domain: No Known Copyright](#)
- Nerve plexus. **Provided by:** Wikipedia. **Located at:** [en.Wikipedia.org/wiki/Nerve_plexus](https://en.wikipedia.org/wiki/Nerve_plexus). License: [CC BY: Attribution](#)
- Brachial plexus 2. **Provided by:** Wikipedia. **Located at:** [en.Wikipedia.org/wiki/File:B...l_plexus_2.svg](https://en.wikipedia.org/wiki/File:B...l_plexus_2.svg). License: [Public Domain: No Known Copyright](#)
- Intercostal nerves. **Provided by:** Wikipedia. **Located at:** [en.Wikipedia.org/wiki/Intercostal_nerves](https://en.wikipedia.org/wiki/Intercostal_nerves). License: [CC BY-SA: Attribution-ShareAlike](#)
- Intercostal nerves. **Provided by:** Wikipedia. **Located at:** [en.Wikipedia.org/wiki/Intercostal_nerves](https://en.wikipedia.org/wiki/Intercostal_nerves). License: [CC BY-SA: Attribution-ShareAlike](#)
- sympathetic trunk. **Provided by:** Wikipedia. **Located at:** [en.Wikipedia.org/wiki/sympathetic%20trunk](https://en.wikipedia.org/wiki/sympathetic%20trunk). License: [CC BY-SA: Attribution-ShareAlike](#)
- thoracic spinal nerves. **Provided by:** Wikipedia. **Located at:** [en.Wikipedia.org/wiki/thoraci...pinal%20nerves](https://en.wikipedia.org/wiki/thoraci...pinal%20nerves). License: [CC BY-SA: Attribution-ShareAlike](#)
- abdominal peritoneum. **Provided by:** Wikipedia. **Located at:** [en.Wikipedia.org/wiki/abdominal%20peritoneum](https://en.wikipedia.org/wiki/abdominal%20peritoneum). License: [CC BY-SA: Attribution-ShareAlike](#)
- Spinal nerves. **Provided by:** Wikipedia. **Located at:** [en.Wikipedia.org/wiki/Spinal_nerves%23Anatomy](https://en.wikipedia.org/wiki/Spinal_nerves%23Anatomy). License: [CC BY-SA: Attribution-ShareAlike](#)
- Spinal Nerve. **Provided by:** Wikipedia. **Located at:** [en.Wikipedia.org/wiki/Spinal_nerve](https://en.wikipedia.org/wiki/Spinal_nerve). License: [CC BY-SA: Attribution-ShareAlike](#)
- Foraminaintervertebralia. **Provided by:** Wikipedia. **Located at:** [en.Wikipedia.org/wiki/File:Fo...ertebralia.png](https://en.wikipedia.org/wiki/File:Fo...ertebralia.png). License: [CC BY-SA: Attribution-ShareAlike](#)

- Gray819. **Provided by:** Wikipedia. **Located at:** [en.Wikipedia.org/wiki/File:Gray819.png](https://en.wikipedia.org/wiki/File:Gray819.png). License: *Public Domain: No Known Copyright*
- Nerve plexus. **Provided by:** Wikipedia. **Located at:** [en.Wikipedia.org/wiki/Nerve_plexus](https://en.wikipedia.org/wiki/Nerve_plexus). License: *CC BY: Attribution*
- Brachial plexus 2. **Provided by:** Wikipedia. **Located at:** [en.Wikipedia.org/wiki/File:Brachial_plexus_2.svg](https://en.wikipedia.org/wiki/File:Brachial_plexus_2.svg). License: *Public Domain: No Known Copyright*
- Gray821. **Provided by:** Wikipedia Commons. **Located at:** [en.Wikipedia.org/wiki/File:Gray821.png](https://en.wikipedia.org/wiki/File:Gray821.png). License: *Public Domain: No Known Copyright*
- Dermatome (anatomy). **Provided by:** Wikipedia. **Located at:** [en.Wikipedia.org/wiki/Dermatome_\(anatomy\)](https://en.wikipedia.org/wiki/Dermatome_(anatomy)). License: *CC BY-SA: Attribution-ShareAlike*
- Dermatomes. **Provided by:** Wikipedia. **Located at:** [en.Wikipedia.org/wiki/Dermatomes](https://en.wikipedia.org/wiki/Dermatomes). License: *CC BY-SA: Attribution-ShareAlike*
- chickenpox. **Provided by:** Wiktionary. **Located at:** en.wiktionary.org/wiki/chickenpox. License: *CC BY-SA: Attribution-ShareAlike*
- shingles. **Provided by:** Wiktionary. **Located at:** en.wiktionary.org/wiki/shingles. License: *CC BY-SA: Attribution-ShareAlike*
- Myotome. **Provided by:** Wikipedia. **Located at:** [en.Wikipedia.org/wiki/Myotome](https://en.wikipedia.org/wiki/Myotome). License: *CC BY-SA: Attribution-ShareAlike*
- Spinal nerves. **Provided by:** Wikipedia. **Located at:** [en.Wikipedia.org/wiki/Spinal_nerves%23Anatomy](https://en.wikipedia.org/wiki/Spinal_nerves%23Anatomy). License: *CC BY-SA: Attribution-ShareAlike*
- Spinal Nerve. **Provided by:** Wikipedia. **Located at:** [en.Wikipedia.org/wiki/Spinal_nerve](https://en.wikipedia.org/wiki/Spinal_nerve). License: *CC BY-SA: Attribution-ShareAlike*
- Foraminointervertebralia. **Provided by:** Wikipedia. **Located at:** [en.Wikipedia.org/wiki/File:Foraminointervertebralia.png](https://en.wikipedia.org/wiki/File:Foraminointervertebralia.png). License: *CC BY-SA: Attribution-ShareAlike*
- Gray819. **Provided by:** Wikipedia. **Located at:** [en.Wikipedia.org/wiki/File:Gray819.png](https://en.wikipedia.org/wiki/File:Gray819.png). License: *Public Domain: No Known Copyright*
- Nerve plexus. **Provided by:** Wikipedia. **Located at:** [en.Wikipedia.org/wiki/Nerve_plexus](https://en.wikipedia.org/wiki/Nerve_plexus). License: *CC BY: Attribution*
- Brachial plexus 2. **Provided by:** Wikipedia. **Located at:** [en.Wikipedia.org/wiki/File:Brachial_plexus_2.svg](https://en.wikipedia.org/wiki/File:Brachial_plexus_2.svg). License: *Public Domain: No Known Copyright*
- Gray821. **Provided by:** Wikipedia Commons. **Located at:** [en.Wikipedia.org/wiki/File:Gray821.png](https://en.wikipedia.org/wiki/File:Gray821.png). License: *Public Domain: No Known Copyright*
- Dermatomes. **Provided by:** Wikipedia. **Located at:** [en.Wikipedia.org/wiki/Dermatomes](https://en.wikipedia.org/wiki/Dermatomes). License: *Public Domain: No Known Copyright*
- Shingles. **Provided by:** Wikipedia. **Located at:** [en.Wikipedia.org/wiki/File:Shingles.JPG](https://en.wikipedia.org/wiki/File:Shingles.JPG). License: *CC BY-SA: Attribution-ShareAlike*
- Human Physiology/The Nervous System. **Provided by:** Wikibooks. **Located at:** en.wikibooks.org/wiki/Human_Physiology/The_Nervous_System. License: *CC BY-SA: Attribution-ShareAlike*
- Peripheral nervous system. **Provided by:** Wikipedia. **Located at:** [en.Wikipedia.org/wiki/Peripheral_nervous_system](https://en.wikipedia.org/wiki/Peripheral_nervous_system). License: *CC BY-SA: Attribution-ShareAlike*
- peripheral nervous system. **Provided by:** Wikipedia. **Located at:** [en.Wikipedia.org/wiki/peripheral_nervous_system](https://en.wikipedia.org/wiki/peripheral_nervous_system). License: *CC BY-SA: Attribution-ShareAlike*
- mixed spinal nerve. **Provided by:** Wikipedia. **Located at:** [en.Wikipedia.org/wiki/mixed_spinal_nerve](https://en.wikipedia.org/wiki/mixed_spinal_nerve). License: *CC BY-SA: Attribution-ShareAlike*
- Autonomic Nervous System. **Provided by:** Wikipedia. **Located at:** [en.Wikipedia.org/wiki/Autonomic_nervous_system](https://en.wikipedia.org/wiki/Autonomic_nervous_system). License: *CC BY-SA: Attribution-ShareAlike*
- Spinal nerves. **Provided by:** Wikipedia. **Located at:** [en.Wikipedia.org/wiki/Spinal_nerves%23Anatomy](https://en.wikipedia.org/wiki/Spinal_nerves%23Anatomy). License: *CC BY-SA: Attribution-ShareAlike*
- Spinal Nerve. **Provided by:** Wikipedia. **Located at:** [en.Wikipedia.org/wiki/Spinal_nerve](https://en.wikipedia.org/wiki/Spinal_nerve). License: *CC BY-SA: Attribution-ShareAlike*
- Foraminointervertebralia. **Provided by:** Wikipedia. **Located at:** [en.Wikipedia.org/wiki/File:Foraminointervertebralia.png](https://en.wikipedia.org/wiki/File:Foraminointervertebralia.png). License: *CC BY-SA: Attribution-ShareAlike*
- Gray819. **Provided by:** Wikipedia. **Located at:** [en.Wikipedia.org/wiki/File:Gray819.png](https://en.wikipedia.org/wiki/File:Gray819.png). License: *Public Domain: No Known Copyright*

- Nerve plexus. **Provided by:** Wikipedia. **Located at:** [en.Wikipedia.org/wiki/Nerve_plexus](https://en.wikipedia.org/wiki/Nerve_plexus). License: [CC BY: Attribution](#)
- Brachial plexus 2. **Provided by:** Wikipedia. **Located at:** [en.Wikipedia.org/wiki/File:Brachial_plexus_2.svg](https://en.wikipedia.org/wiki/File:Brachial_plexus_2.svg). License: [Public Domain: No Known Copyright](#)
- Gray821. **Provided by:** Wikipedia Commons. **Located at:** [en.Wikipedia.org/wiki/File:Gray821.png](https://en.wikipedia.org/wiki/File:Gray821.png). License: [Public Domain: No Known Copyright](#)
- Dermatomes. **Provided by:** Wikipedia. **Located at:** [en.Wikipedia.org/wiki/Dermatomes](https://en.wikipedia.org/wiki/Dermatomes). License: [Public Domain: No Known Copyright](#)
- Shingles. **Provided by:** Wikipedia. **Located at:** [en.Wikipedia.org/wiki/File:Shingles.JPG](https://en.wikipedia.org/wiki/File:Shingles.JPG). License: [CC BY-SA: Attribution-ShareAlike](#)
- The Autonomic Nervous System. **Provided by:** Wikipedia Commons. **Located at:** commons.wikimedia.org/wiki/File:The_Autonomic_Nervous_System.jpg. License: [Public Domain: No Known Copyright](#)
- Spinal nerves. **Provided by:** Wikipedia. **Located at:** [en.Wikipedia.org/wiki/Spinal_nerves](https://en.wikipedia.org/wiki/Spinal_nerves). License: [Public Domain: No Known Copyright](#)

12.6F: Function and Physiology of the Spinal Nerves is shared under a [CC BY-SA](#) license and was authored, remixed, and/or curated by LibreTexts.